
An Electrical Impedance Mammographic Scheme – Norms and Pathology

Alexander Karpov, Andrey Kolobanov and
Marina Korotkova

Additional information is available at the end of the chapter

<http://dx.doi.org/10.5772/60014>

1. Introduction

1.1. The concept of a normal mammographic scheme: mammographic schemes in diagnostics

A normal mammographic scheme in traditional diagnostic techniques (X-ray, US) is a set of anatomic structures regularly found on normal mammograms. Existing classifications of normal breast X-ray anatomic pictures help distinguish several structural types of the breast. Each structural type is presented by a certain morphological substrate (Figure 1). Wolfe's Classification (1976),

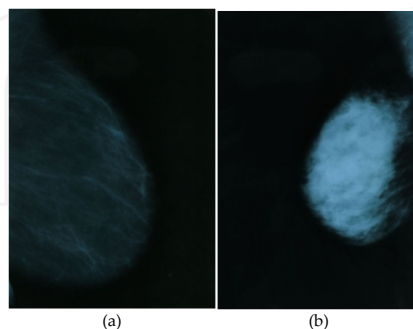


Figure 1. (a) Predominantly fatty normal mammogram; (b) dense normal mammogram.

Tabar's Classification (1997), Boyd's Classification (1980) and the BI-RADS Classification (2000) are the most widely-known [1, 2, 3]. According to Wolfe, breast structural types are defined by the ratio of fat to ducts: N1 – the breast consists mainly of fat; P1 – linear densities occupy no more than 25% of the breast; P2 – linear densities occupy more than 25% of the breast; D_y – dense. Tabar relies on histomammographic correlations and distinguishes five types of breast structure: I – a balanced proportion of all components of the breast tissue; II – fat breasts; III – a predominance of fat tissue with retroareolar residual fibrous tissue; IV – predominantly nodular densities; V – dense breasts. Boyd takes a different approach, introducing a quantitative evaluation of the breast structure: A – 0% mammographic density; B – >0-10%; C – >10-25%; D – >25-50%; E – >50-75%; F – >75%. The BI-RADS classification modifies that worked out by Wolfe, expressing a breast density percentage and adding a division into quartiles: Type 1 – extremely fat, with parenchyma below 25%; Type 2- minimal density, parenchyma 25-50%; Type 3 – heterogeneous density, parenchyma 50-75%; Type 4 – extremely dense, parenchyma 75-100%. Thus, breast structural types have been defined in reliance on the correlation between the ductal component and fat lobules. The breast has a variable appearance in each case and the breast density decreases after the menopause. It should be noted that no similar system of breast structural types has been developed by reference to the US.

A distortion of the normal mammographic scheme is observed when structural changes appear, in the form of pathological shadows and microcalcinations. Such focal changes are easily detected by medical devices diagnosing using tissue density. However, focal changes are not the only mode of cancer manifestation. Diffuse changes of the breast structure may also stand for a malignant process and may equally result in the distortion of the mammographic scheme. Diffuse changes do not affect breast tissue density and present certain difficulties for X-ray diagnostics.

2. Electrical impedance images

Electrical impedance mammography is a medical imaging technique aimed at creating images of the breast by means of external scanning. Electrical impedance mammography measures electromagnetic phenomena and belongs to non-invasive techniques of image creation [4].

There exist two types of techniques creating tomographic images: local and non-local. X-ray computer tomography, magnetic resonance tomography and positron emission tomography belong to local techniques, implying the passage of one direct ray through the body and the creation of one pixel in the image (one ray – one pixel). The pixel value depends solely on the substance that the ray meets on its way. Using multiple angles for calculation captures two-dimensional slices that can be reconstructed for obtaining three-dimensional images of the object scanned.

Electrical impedance mammography belongs to the category of soft-field tomography and uses a non-local technique for image creation, whereby all points on the object scanned affect the

measurement result. This is why the value of the mean electrical conductivity is dominant in detecting focal changes.

We use the electrical impedance computer mammographer MEIK 5.6 for the creation of electrical impedance images [5, 6]. The mammographer has the following key characteristics:

- **Electrode configuration.** A planar set of electrodes is used for the procedure. Electrodes configured in this way have a coplanar location. In our case, the electrodes are arranged on the platform of the mammographer, which is pressed to the breast and immobilized manually. The advantages of using electrodes with a planar configuration include the following. First, the electrodes are fixed onto the panel so that their position is exact. This allows the avoidance of any positional error. Second, the scanning panel is handy and manoeuvrable, so it can be easily moved along the patient's body. This means that the device is designed for real-time use. Third, the sensitivity of the linear electrodes is relatively more concentrated than that of the electrodes surrounding the area of interest in the form of a circle, which is why the resolution may increase locally.
- **Data collection method.** When carrying out an electrical impedance examination, a set of electrodes is placed on the object's surface. A part of each electrode is used as an inductor, the other part as a measuring electrode. An electrical supply is generally used as an inductor, while the difference in the electric potential is measured between the measuring electrodes. All the measurements are done on the object's surface. The main goal is to reconstruct the volumetric distribution of the object's conductivity with the results of the electric measurements on its surface.
- **Image reconstruction algorithm.** A back-projection algorithm is used for the reconstruction of a volumetric static frequency image along the equipotential surfaces of the electric field with the weight function applied both horizontally and vertically. The image is reconstructed in layers that are located parallel to the panel with the electrodes. The back-projection method was originally worked out as an empirical method. It was based on the idea of the direct distribution of scanning radiation in the tissue (i.e., the presence of rays). Electrical impedance mammography is not based on the use of rays, which leads us to introduce the term 'pseudoray'. The use of this term is justified by the fact that the change in the superficial difference of electric potential (as compared to homogeneous tissues) invoked by the presence in the object of a local non-homogeneous area is generally concentrated in the segment that is a projection of the non-homogeneity onto the object's surface along the equipotential lines (or surfaces) of the field.

Thus, the method of back-projection may be applied to the case when the power lines of electric field intensity are used instead of rays, the former being estimated for the case of homogeneous conductivity distribution [7].

A two-dimensional image is a good way to illustrate the method. The figure on the left (Figure 2) shows systems of equipotential lines for two injecting electrodes $i(A)$ and $i(B)$.

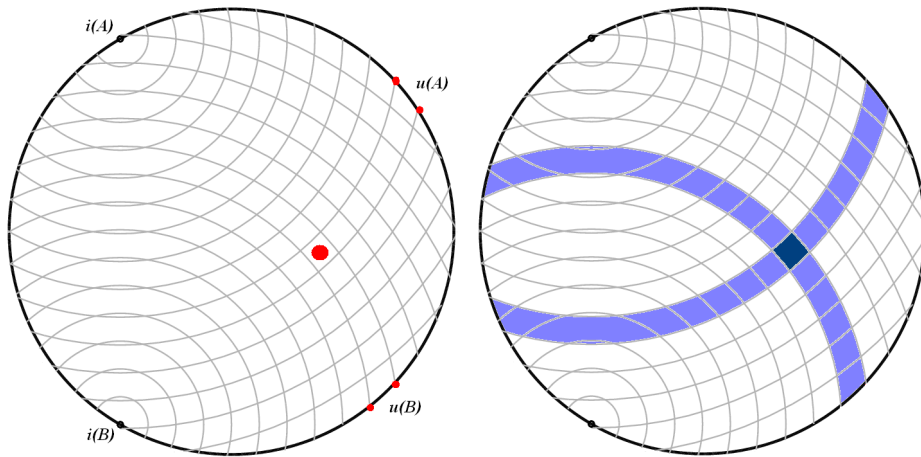


Figure 2. Equipotential lines – pseudorays and image reconstruction.

Here, we present the case of a diametrical location of an injection electrode pair (the opposing referent electrode is not shown in the figure). The red spot stands for a non-homogeneous area in the object. The red dots on the surface of the object show pairs of measuring electrodes in which the electric potential differences $u(A)$ and $u(B)$ diverge maximally as compared to areas with a homogeneous distribution of electrical conductivity. The figure on the right demonstrates the principle of image reconstruction based on measurement results obtained from two injecting electrodes. The light blue lines show the noise components of the reconstructed image. The dark blue cross-section is a constructed image of the non-homogeneous area. The image will be of better quality when reconstructed by measurement results from a greater number of injecting electrodes.

The key differences between the three-dimensional image and the two-dimensional image involve the following:

- Equipotential surfaces have a spherical shape with a centre in the injecting electrode;
- The projection of an isolated non-homogeneity along the equipotential lines onto the object's surface has a spherical shape with a centre in the injecting electrode and a radius equal to the distance from the injecting electrode to the non-homogeneity;
- The change in the superficial potential differences (as compared to the homogeneous tissues) is generally concentrated in the circle shown above, and decreases as the distance between the point in the circle and the non-homogeneity becomes greater.

Thus, the back-projection method in a three-dimensional image consists of the usual projection of the superficial potential difference change (as compared to the homogeneous tissues) into the object along the equipotential surfaces, but with a weight depending on the distance between the projected point and the point at which conductivity reconstruction occurs [7].

3. Elements of electrical impedance in a mammographic scheme

Here, we present a description of breast anatomic structures and comment on the concept of a mammographic scheme in terms of electrical impedance mammography [8].

3.1. Terminology

- Electrical conductivity scale - electrical conductivity index values from 0 to 1.00; or in grey-scale - changes from black to white, respectively.
- Hyperimpedance structure, lesion – the electrical conductivity is lower than the electrical conductivity of the surrounding tissue of the breast and corresponds to $IC < 0.20$.
- Isoimpedance structure, lesion – the electrical conductivity is approximately equal to the electrical conductivity of the surrounding tissue of the breast and corresponds to $IC = 0.30-0.50$ (this depends on the value of the mean electric conductivity).
- Hypoimpedance structure, lesion – the electrical conductivity is higher than the electrical conductivity of the surrounding tissue of the breast and corresponds to $IC = 0.60-0.80$ (this depends on the value of the mean electric conductivity).
- Animpedance structure, lesion – the electrical conductivity is considerably higher than the electrical conductivity of the surrounding tissue of the breast and corresponds to $IC > 0.80$ (this depends on the value of the mean electric conductivity).
- IC – index conductivity.

In the anatomy of the mammary gland, the following elements of the electrical mammographic scheme can be marked out: capsule, connective tissue carcass, parenchyma, secretory reservoir, nipple and areola.

3.2. Capsule

The mammary gland capsule consists of leaves of the superficial fascia and subcutaneous fat enveloping the mammary gland on all sides.

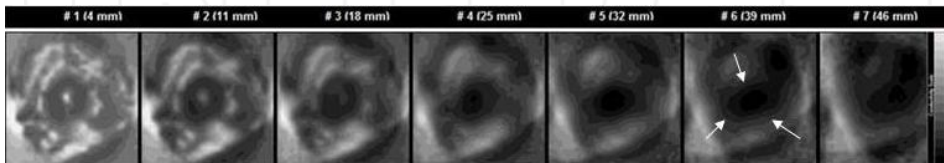


Figure 3. Electrical impedance tomogram of the mammary gland (EIM). Seven planes of scanning. In the sixth and the seventh scans, a retromammary tissue is visualized.

In the image, the capsule forms an important element of the mammographic scheme – the mammary gland contour – with fatty tissue intimately embracing the body of the mammary

gland (capsulaadiposammae). The front layer of the capsule ends in the behind-areola area where the ends of the milk duct are situated. In figure 3, one can see an electrical impedance tomogram where fatty tissue on the periphery of the mammary gland is represented in the shape of a hyperimpedance contour.

3.3. Carcass

The mammary gland is enclosed in a connective tissue capsule, sending septa into the strata of the gland. The septa consist of tender fibrillary tissues and are situated between the glandular elements. The septa that form the connective tissue framework of the mammary gland are in hyperimpedance and radically diverge from the areola. On the periphery of the mammary gland, the adipose capsule stands out in the form of a hyperimpedance contour (Figure 4).

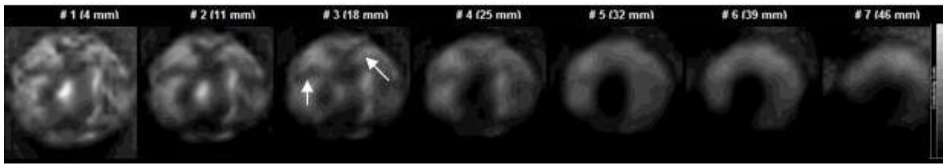


Figure 4. EIM. Seven planes of scan. In the first, second and third scans, the connective tissues' septa are visualized along with the radially diverging areolae.

3.4. Parenchyma

The parenchyma is a structural component of the mammary gland made of alveotubular glands and the connective tissue stroma. Alveotubular glands consisting of ductal and secretory epithelium are gathered into small lobules forming lobes. The connective tissue stroma is represented by a small number of cells, gentle tissues and the base material. Figure 5 shows an electrical impedance tomogram, where the parenchyma is represented in the form of isoimpedance areas visible between the septa.

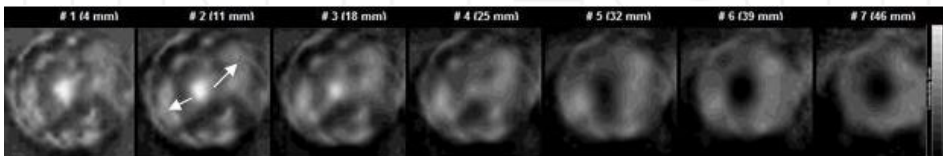


Figure 5. EIM. Seven scan planes. The parenchyma is visualized in the form of isoimpedance areas between the connective tissue septa.

3.5. Secretory reservoir

Before opening into the nipple milk ducts enlarge and form a lactiferous sinus (sinus lactiferi). It which accumulates secretion or milk produced in alveoli and is characterized by low electrical impedance. There are 15-25 such sinuses in the area behind the nipple. In Figure 6, one can see an electrical impedance tomogram where the lactiferous sinus zone visualizes itself as a vast hypoiimpedance area, situated in the centre of the mammogram.

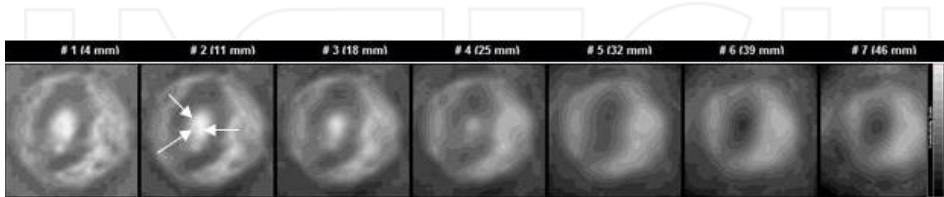


Figure 6. EIM. Seven scan planes. In the centre of the tomogram there is a hypoiimpedance area corresponding to the location of the lactiferous sinuses.

3.6. Nipple and areola

The nipple of the mammary gland and the mammary areola are areas of hairless pigmented epidermis. The nipple consists of the lactiferous sinus, an extension into which flows the excretory ducts of the mammary gland lobules, with fibrous tissue around them, and a large number of sebaceous glands. The absence in the nipple of the perspiratory gland's excretory ducts defines its high electrical impedance. The nipple is visible in the first and second scans of the electrical impedance tomogram, taking the form of a linear hyperimpedance formation located in the centre, near the zone of the lactiferous sinuses (Figure 7).

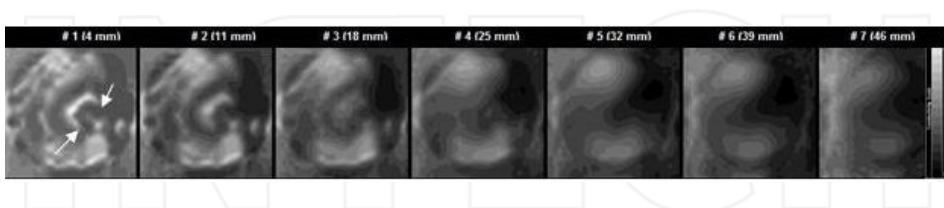


Figure 7. EIM. Seven scan planes. Outer segment. In the center of the 1st and the 2nd scans a linear hyperimpedance formation typical of the nipple is visualized.

The derma of the mammary areola contains a large number of pigmentary cells which condition its high electrical impedance. On the electrical impedance tomogram, the mammary areola is visualized as a hyperimpedance formation of a round shape around the area of the lactiferous sinuses (Figure 8).

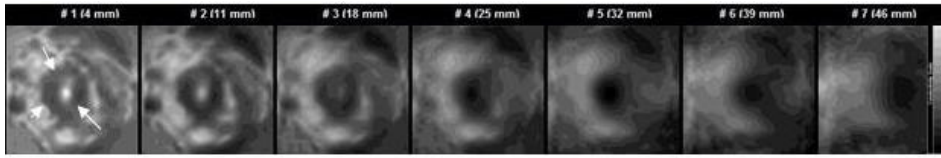


Figure 8. Impedance area in the centre of the tomogram corresponding to the placement of the areola.

4. Normal electrical impedance mammographic scheme

As has been mentioned above, the breast may have a variable appearance on the tomogram. This is why the electrical impedance mammographic scheme depends on the type of breast structure. Earlier, we pointed out five types of breast structure from the point of view of electrical impedance mammography execution (Table 1).

	<i>EIM classification</i>	<i>ACR classification</i>
Type Ia	Amorphous type of mammary gland structure. IC = above 0.66 *IC – index conductivity	Predominantly fat. Under 25% of the tissue is represented by the parenchyma.
Type Ib	Mixed type of mammary gland structure with amorphous component predominance. IC=0.57-0.65.	
Type II	Mixed type of mammary gland structure. IC=0.30-0.56	Fat with some fibroglandular tissue. 25-50% of the tissue is represented by the parenchyma.
Type III	Mixed type of mammary gland structure with an acinal/ductal component predominance. High density of the acinal/ductal component. IC=0.22-0.29.	Heterogeneously dense. 50-75% of the tissue is represented by the parenchyma.
Type IV	Acinal/ductal type of mammary gland structure. Extremely high density of the acinal/duct component. IC <0.22.	Extremely dense. 75-100% of the parenchyma tissue.

Table 1. Mammary gland structure from the perspective of electrical impedance mammography execution, and breast density types according to the classification of the American College of Radiology (ACR).

4.1. Normal mammographic scheme with a ductal-type mammary gland structure

The prevailing ductal component in the parenchyma structure is typical of women during the early reproductive period. The high density of the ductal component is a significant obstacle

in the way of electric charges, which adds specific features to the electrical impedance image: the prevalence of darker tones of greyscale; well-defined anatomical landmarks; low values of electrical conductivity. In the normal electrical impedance mammographic scheme, the anatomical landmarks are distinct and well-defined.

- The mammary gland contour is even and regular, without extrusions, retractions or unilateral thickening (Figure 9).

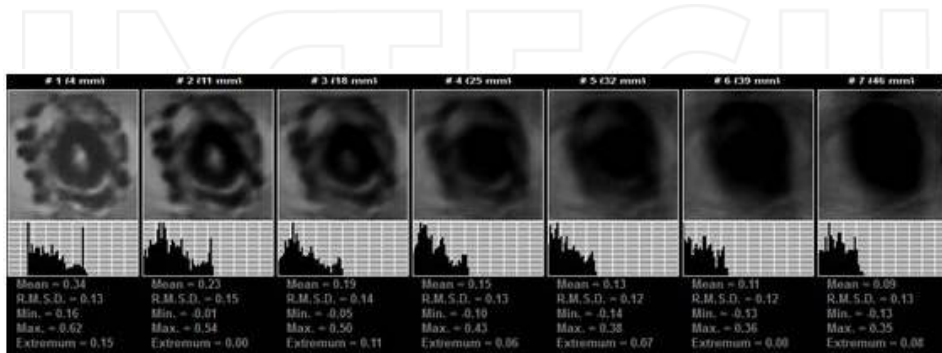


Figure 9. EIM. Seven scan planes. The mammary gland contour is distinct and without deformation.

- The areola is in the centre of the image, non-displaced, non-deformed, non-fragmented and coloured in black tones of greyscale (Figure 10).

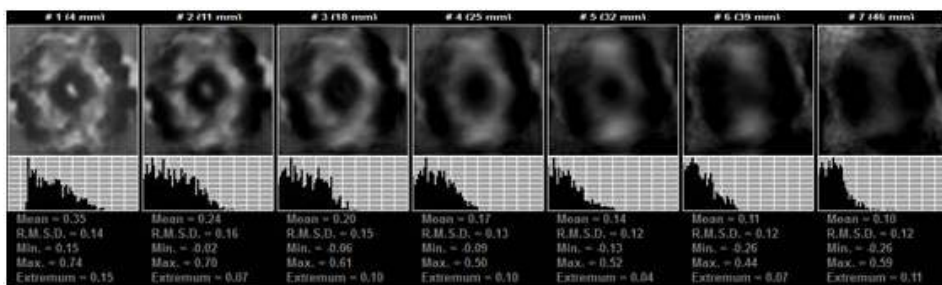


Figure 10. EIM. Seven scan planes. Central location of the areola. The areola is black.

- The mammary gland structure is represented by the parenchyma and the septa without focal changes (Figure 11).

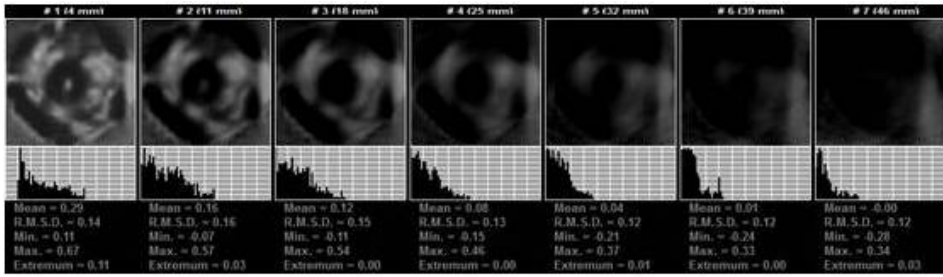


Figure 11. EIM. Seven scan planes. The parenchyma is without focal changes.

- The relative electrical conductivity of the left and right breasts is within normal range – the divergence of the electrical conductivity histograms is less than 20% (Figure 12).

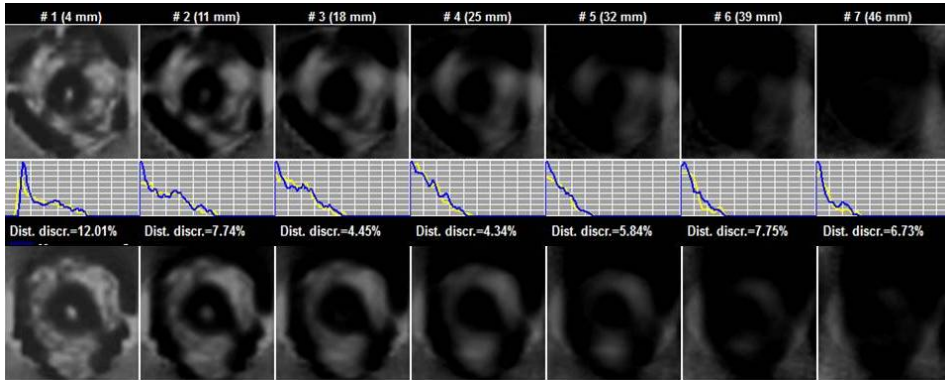


Figure 12. EIM. Seven scan planes. The top row shows images of the left breast, the bottom shows images of the right breast. The middle row presents a comparison of conductivity distribution histograms.

4.2. Normal mammographic scheme for amorphous-type breast structures

The predominance of an amorphous substance in the breast parenchyma structure can be observed among peri-menopausal and menopausal women. A considerable amount of fibrous friable connecting tissue in the mammary gland with a predominance of the basic substance helps the electric charge to pass. This conditions the characteristic features of the electrical impedance image: the predominance of lighter tones of greyscale; an absence of anatomic landmarks; high values of electrical conductivity. A normal electrical impedance mammographic scheme is expected to have all the characteristic features.

- The mammary gland contour is even and regular, without extrusions, retractions or unilateral thickening (Figure 13).

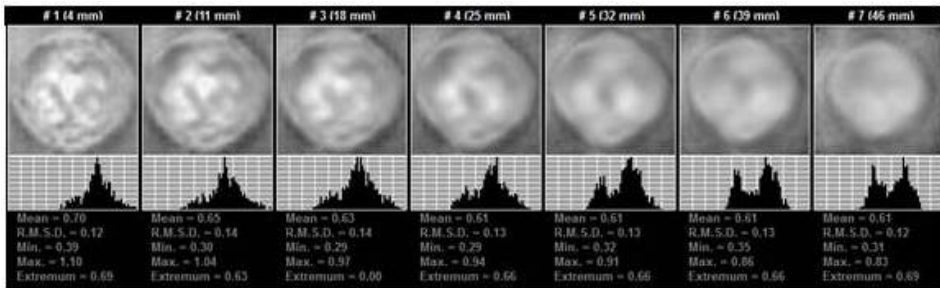


Figure 13. EIM. Seven scan planes. The mammary gland contour is distinct and without deformation.

- The areola is in the centre of the image, non-displaced, non-deformed, non-fragmented and coloured in white tones of greyscale (Figure 14).

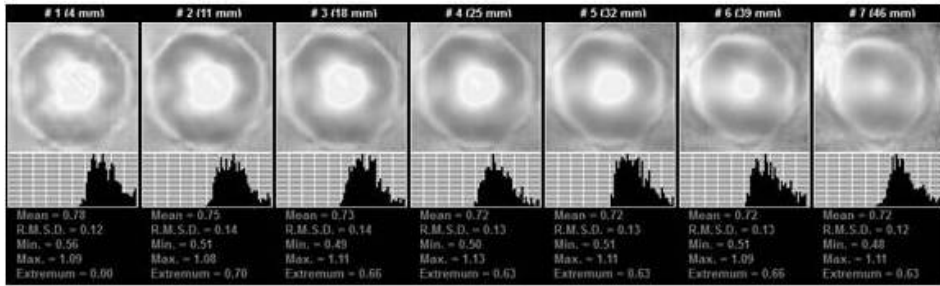


Figure 14. EIM. Seven scan planes. Central location of the areola. The areola is white.

- The mammary gland parenchyma is visualized as an unstructured mass, without septa and without focal changes (Figure 15).

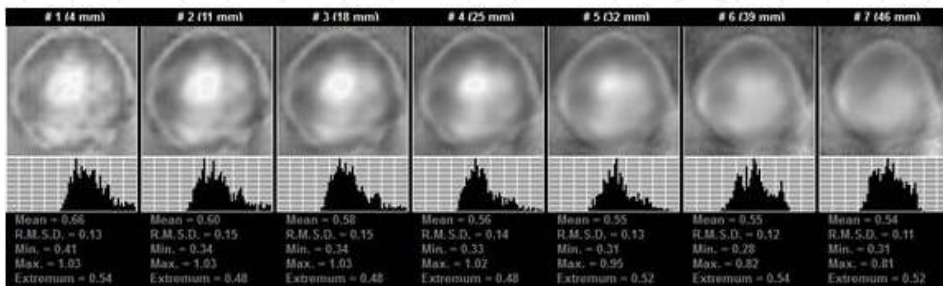


Figure 15. EIM. Seven scan planes. The parenchyma is without focal changes.

- The relative electrical conductivity of the left and right breasts is within normal range – the divergence of electrical conductivity histograms is less than 20% (Figure 16).

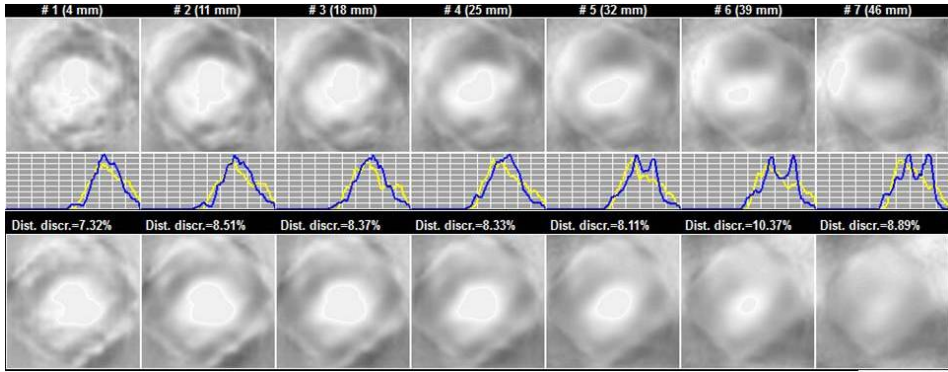


Figure 16. EIM. Seven scan planes. The top row shows images of the left breast, the bottom – of the right. The middle row demonstrates the comparison of conductivity distribution histograms.

4.3. Normal mammographic scheme for mixed-type breast structures

A mixed-type breast structure combines the elements of the ductal and amorphous types. Different combinations of these structures define the differing electrical conductivity of tissues and affect the electrical impedance image. The breast parenchyma becomes ‘poorer’ and homogeneous.

- The mammary gland contour is even and regular, without extrusions, retractions or unilateral thickening (Figure 17).

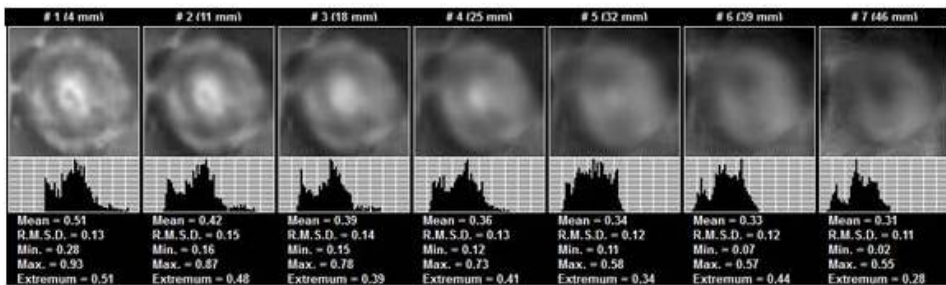


Figure 17. EIM. Seven scan planes. The mammary gland contour is distinct and without deformation

- The areola is in the centre of the figure, non-displaced, non-deformed, non-fragmented and the colour is variable (Figure 18).

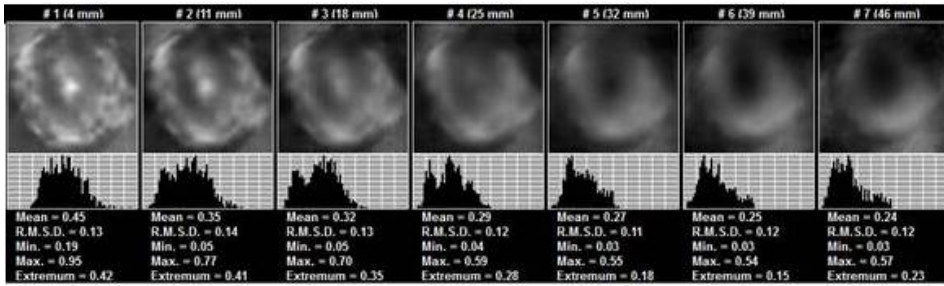


Figure 18. EIM. Seven scan planes. Central location of the areola.

- The mammary gland parenchyma is variable and without focal changes (Figure 19).

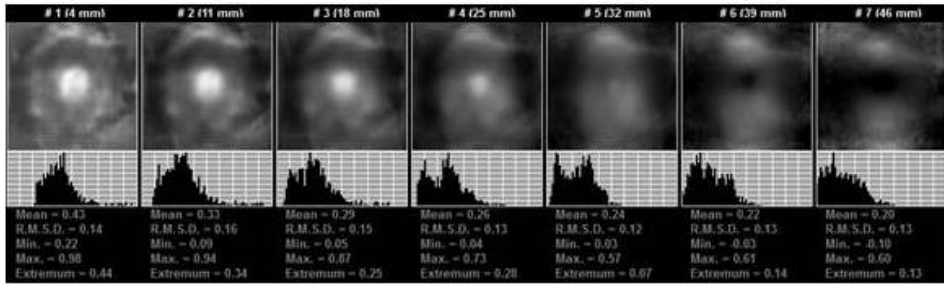


Figure 19. EIM. Seven scan planes. The parenchyma is without focal changes.

- The relative electrical conductivity of the left and right breasts is within normal range – the divergence of electrical conductivity histograms is less than 20% (Figure 20).

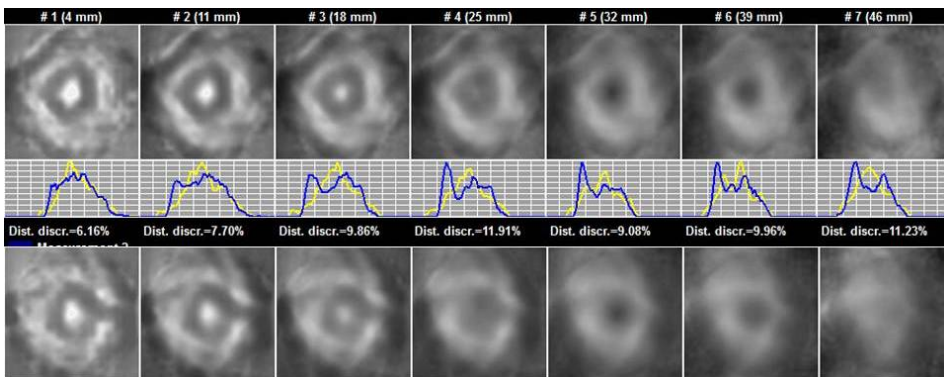


Figure 20. EIM. The top row shows images of the left breast, the bottom shows images of the right. The middle row demonstrates the comparison of the conductivity distribution histograms.

5. Electrical impedance mammographic scheme distortion in the presence of cancer

Here, we present the prospective assessment results of 310 cases of verified breast cancer. Electrical impedance mammograms were received from oncological centres in Russia, Belarus, South Africa and Malaysia. As a result, the mammographic scheme distortion was revealed in 74% of cases, whereas the change in the general electrical conductivity was detected in 67% of cases. Notably, this does not depend on the tumour size.

The assessment criteria of the mammographic scheme distortion included:

1. Alteration of the mammary gland contour
2. Alteration of the breast anatomy
3. Local electrical impedance alterations
4. Change of relative electrical conductivity

5.1. Mammary gland contour change

The visual assessment of the mammary gland image should start with the analysis of the breast contour. Usually, the contour of the mammary gland is even and regular, non-deformed and without an isoimpedance structure. In the presence of breast cancer, there is a chance of contour deformation and its hyperimpedance.

5.1.1. Contour deformation

Mammary gland contour deformation is an important diagnosis criterion in the presence of certain breast diseases. More often than not, deformation is caused by volumetric processes in the mammary gland, such as cancer. Cancer infiltration of tissues causes local contour deformations in the form of extrusion or retraction. In the top row, one can see images of a malignant breast with local contour deformation in the form of extrusion. The bottom row shows a tomogram of the normal breast (Figure 21).

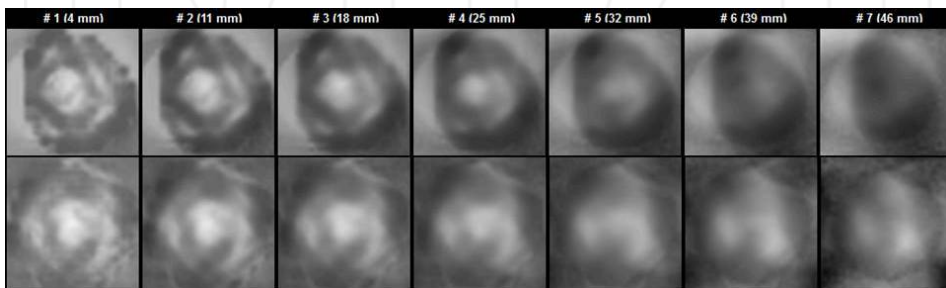


Figure 21. EIM. Seven scan planes. The top row shows images of a malignant breast.

A hyperimpedance contour with a protruding deformity is visible at 11 o'clock. The bottom row shows images of the normal breast.

5.1.2. Thickening and hyperimpedance of the contour

By contour hyperimpedance, one should understand a significant increase of electrical impedance on the periphery of the mammary gland. This phenomenon – unilateral as a rule – should be considered as a reaction of the breast tissues solely in response to a malignant process (Figure 22).

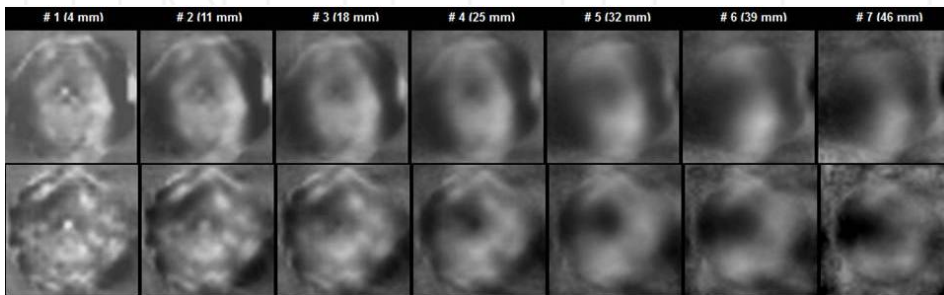


Figure 22. EIM. Seven scan planes. The top row shows images of a malignant breast. The bottom row shows images of the normal breast. A unilateral thickened hyperimpedance contour can clearly be seen.

In the electrical impedance image, a hyperimpedance contour is thickened and intensively black in colour. The top rows of the figures present tomograms with hyperimpedance contours of malignant breasts. In the bottom rows, tomograms of normal breasts are given. The contour hyperimpedance is revealed through the change in its colour and its significant thickening compared to the normal breast (Figure 23).

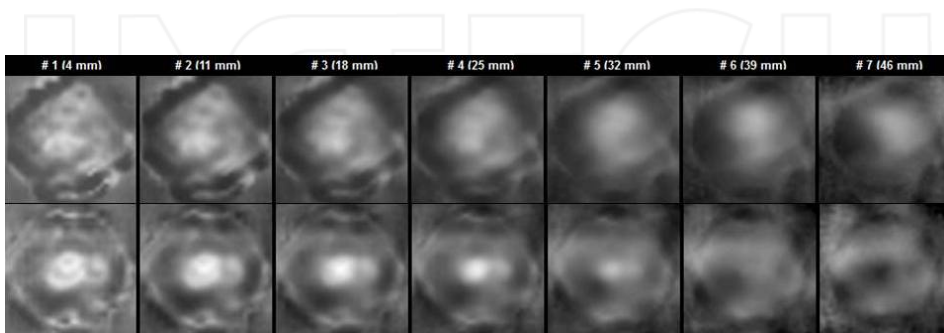


Figure 23. EIM. Seven scan planes. The top row shows images of a malignant breast. The bottom row shows images of the normal breast. A unilateral thickened hyperimpedance contour can be clearly seen.

5.2. Breast anatomy changes

Normally, an image of the mammary gland has an anatomy corresponding to the age-norm, with no shift of the inner structures.

In the presence of breast diseases, the breast anatomy undergoes changes. In Figures 24 and 25, we can clearly see the alteration of the mammary gland anatomy in the presence of cancer (top row) as compared to the images of the normal breast (bottom row).

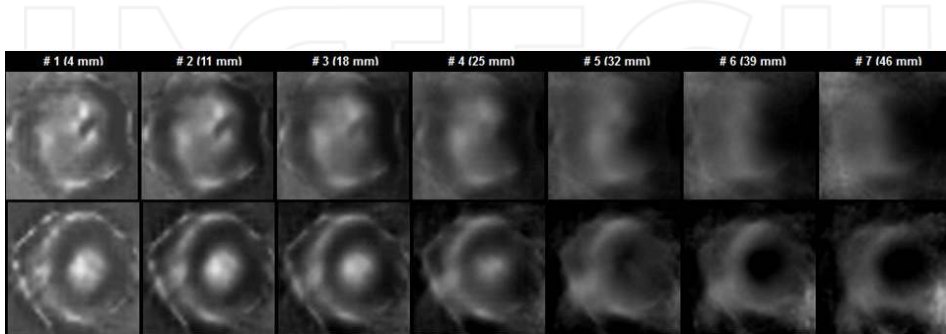


Figure 24. EIM. Seven scan planes. The top row shows images of a malignant breast, the bottom row shows images of the normal breast. A substantial change in the anatomy of the malignant breast accompanied by numerous hyperimpedance enclosures can clearly be seen.

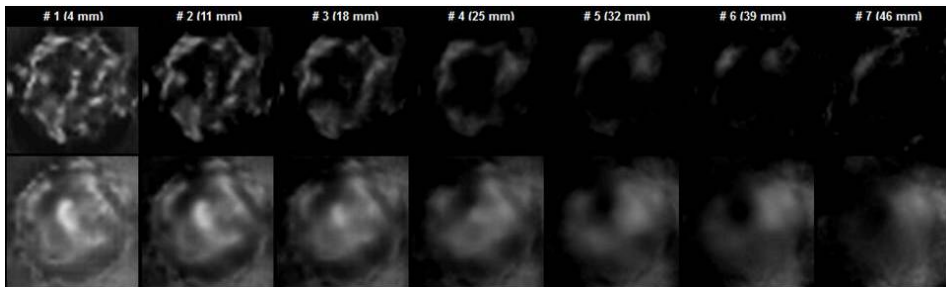


Figure 25. EIM. Seven scan planes. The top row shows images of a malignant breast, the bottom row shows images of the normal breast. No anatomic landmarks are visible in the malignant breast.

5.3. Local electrical conductivity changes

Some of the most important elements of image assessment are local electroconductivity changes outside the lacteous sinus area, and are uncommon in relation to the norm. In the presence of breast diseases, both areas with high impedance (i.e., hyperimpedance area) and areas with low impedance (i.e., hypoimpedance area) can be visualized.

5.3.1. Local hyperimpedance

This figure presents an image of a malignant breast. A focal change of electric conductivity in the form of a non-homogeneous hyperimpedance area with sharp contours and local contour-thickening is visible at eight o'clock. Such changes are typical of an infiltrative process. The bottom row shows images of the normal breast (Figure 26).

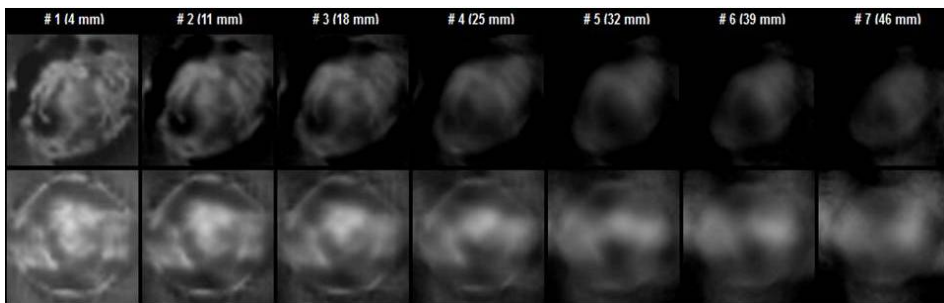


Figure 26. EIM. Seven scan planes. The top row shows images of a malignant breast. A focal change of electric conductivity in the form of a non-homogeneous hyperimpedance area is visible at eight o'clock. The bottom row shows images of the normal breast.

5.3.2. Local hypoimpedance

Focal changes of electric conductivity in the form of a hypoimpedance area with indistinct contours are visible at 11 o'clock. This is also typical of cancer (Figure 27).

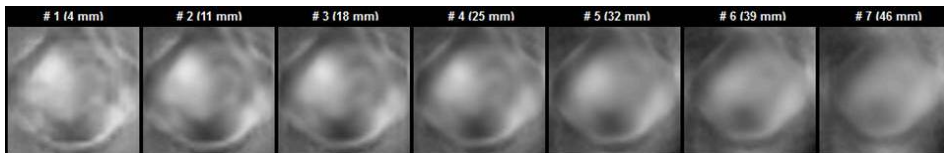


Figure 27. EIM. Seven scan planes. Focal changes of electric conductivity in the form of a hypoimpedance area with indistinct contours are visible at 11 o'clock.

In addition, in the presence of breast cancer, a hyperimpedance contour can be visualized around the infiltration zone. The top row shows images of the malignant breast. A focal change of electric conductivity visualizing itself as an irregularly-shaped area with a hyperimpedance contour and a hypoimpedance structure can be found at two o'clock. The bottom row shows images of the normal breast (Figure 28).

5.3.3. Total hyperimpedance

There are cases of electrical conductivity disturbance that reveal themselves as total impedance increases. This can be observed during the infiltrative oedematous form of breast cancer. In

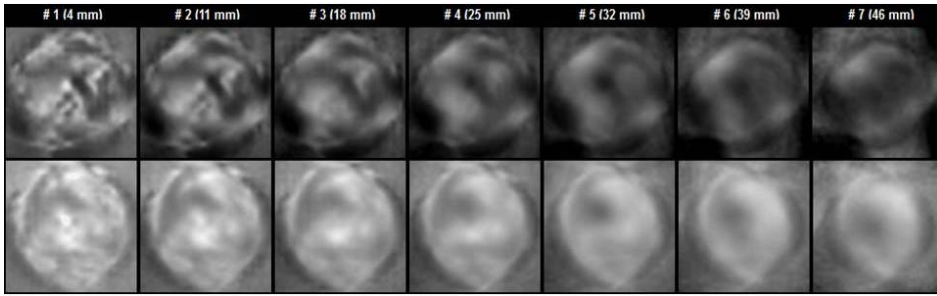


Figure 28. EIM. Seven scan planes. The top row shows images of a malignant breast. A focal change of electric conductivity visualizing itself as an irregularly-shaped area with a hyperimpedance contour and a hypoiimpedance structure can be found at two o'clock. The bottom row shows images of the normal breast.

the figures, the top row presents a breast with total high impedance, which is common for cancer. In the bottom row, there is a tomogram of a normal breast (Figure 29).

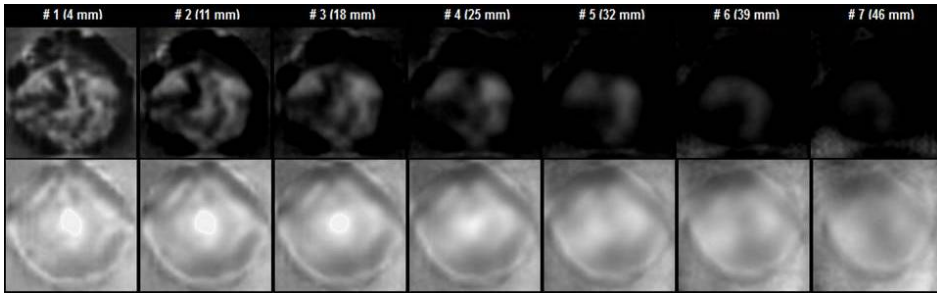


Figure 29. EIM. Seven scan planes. The top row shows images of a malignant breast. The bottom row shows images of a normal breast. The image of the malignant breast is dominated by hyperimpedance tones due to the decrease in electric conductivity.

5.4. Change of relative electrical conductivity

Unlike other methods of visualization, the electrical impedance method makes the quantitative analysis of the image possible. The quantitative analysis of the electrical impedance image implies the assessment of the following parameters: mean electrical conductivity index; histogram of conductivity distribution; comparison with the reference data. To attribute patients to a certain class (healthy or diseased), we have applied the following: the criterion of difference in the form of distributions; the λ criterion; the Kholmogorov-Smirnov criterion (or the DX statistics); an intermediate index in Kholmogorov-Smirnov's computations. This criterion, relating to nonparametric criteria, allows the assessment of the statistical significance of divergences in the distribution of any mark of the norm or pathology, including the electrical conductivity distribution on electrical impedance tomograms. The Dx statistics permit the assessment of the surface of one of the distributions which is not common with the second distribution. The Dx value reflects the share of observations or data which distinguish the

experience (patient) from the control (norm) group. This value is important, both for the substantiation of the diagnosis and the assessment of the information value of the index. A high informative value of differences revealed allows the attribution of the patient to one class or another (e.g., norm or cancer). In order to determine the informative capacity of distribution divergence, we used the information measure of S. Kullback, which demonstrated the informativity of the applied Dx statistics and the input of this index in disease diagnosis, for example, cancer. The assessment of the distribution divergence yielded results which are in direct dependency on the value according to S. Kullback [9] (Table 2).

Distribution divergence	Informative value	Reliability
Up to 20%	very low	no
20-30%	relatively low	yes
30-50%	good	yes
50-65%	high	yes
70-85%	extremely high	yes

Table 2. Informative content and accuracy for different values (%) of conductivity distribution diversion.

In the presence of diseases, mammary gland histogram offset takes place (Figure 30).

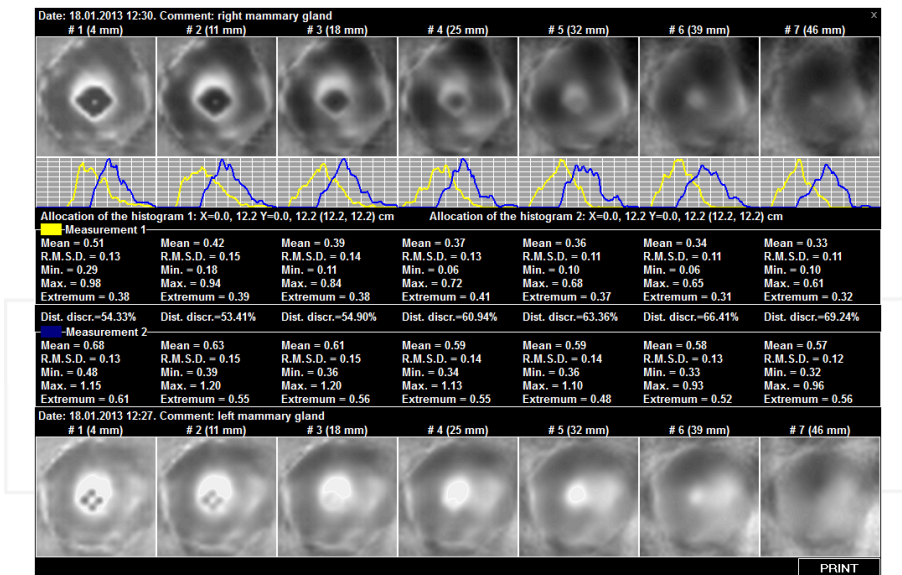


Figure 30. Upper row – EIM. Seven scan planes. Breast cancer. Bottom row - EIM. Seven scan planes. Healthy gland. The second row shows the divergence between the histograms of the electrical conductivity distribution of the affected and healthy glands. Table 3, below, contains the data on the relative conductivity of malignant breasts as compared to breasts undergoing benign changes, normal breasts and breasts with different anatomies.

	Number of patients	Relative conductivity (diseased - healthy mammary gland)					
		< 20%	20-30%	30-40%	40-50%	50-60%	>60%
Cancer	310	101 (33%)	67 (22%)	44 (14%)	37 (12%)	26 (8%)	35 (11%)
Healthy	161	157 (98%)	4 (2%)	0	0	0	0
Healthy Acinal/ductal-type mammary gland structure.	20	18 (90%)	1 (5%)	1 (5%)	0	0	0
Healthy Amorphous-type mammary gland structure.	32	28 (88%)	2 (6%)	2 (6%)	0	0	0
Benign	68	59 (87%)	7 (10%)	2 (3%)	0	0	0

Table 3. Relative breast conductivity for the norm and pathology.

As the oncological process develops, the overall and local conductivity changes. At the same time, the distortion of the normal mammographic scheme can already be observed at the initial stages of the disease. It is for this reason that the given criterion is included in the EIM scale of breast cancer diagnosis (Table 4).

Diagnostic criteria	Electrical impedance mammography points
Shape	
• round, oval	1
• lobular, irregular	2
Contour	
• no	0
• sharp	1
• hyperimpedance, indistinct	2
Surrounding tissues	
• preserved	0
• structure alteration/displacement	1
• thickening/extrusion/retraction	2
Internal electrical structure	
• hyperimpedance ($IC_{roi} < IC_{av} + 2std$)	0
• isoimpedance ($IC_{roi} = IC_{av} \pm 2std$)	1
• hypoimpedance ($IC_{roi} > IC_{av} + 2std$)	2
• animpedance ($IC_{roi} > IC_{av} + 3std$)	3

Diagnostic criteria	Electrical impedance mammography points
Comparative electrical conductivity	
• divergence between the histograms < 20%	0
• divergence between the histograms 20-30 %	1
• divergence between the histograms 30-40%	2
• divergence between the histograms > 40%	3

Table 4. Diagnostic criteria for differentiating volumetric lesions in electrical impedance mammography.

6. Conclusion

The alteration of the normal mammographic scheme along with the abnormal changes of local conductivity is one of the early diagnostic criteria for breast cancer.

Electrical impedance mammography represents a method allowing the formation of observation and risk groups for the development of breast cancer through the use of data on relative electrical conductivity and the age-related electrical conductivity scale.

Complications of the oncological process with oedema are a serious obstacle for X-ray and US diagnostics. Unlike the aforementioned methods of diagnosis, electrical impedance tomography makes it possible to visualize pathophysiological changes in such states as cancer, mastitis and lymphostasis, etc.

Author details

Alexander Karpov^{1*}, Andrey Kolobanov² and Marina Korotkova¹

*Address all correspondence to: karpovay@medyar.ru

1 Clinical Hospital #9, Yaroslavl, Russia

2 Railroad Clinical Hospital, Yaroslavl, Russia

References

- [1] Boyd NF, Byng JW, Jong RA, Fishell EK, Little LE, Miller AB, Lockwood GA, Tritcher DL, Yaffe MJ. Quantitative classification of mammographic densities and breast cancer risk: results from Canadian National Breast Screening Study. *J. Natl. Cancer Inst.* 1995; 87: 670-675.

- [2] Wolfe JN, Saftias AF, Salane M. Mammographic parenchymal patterns and quantitative evaluation of mammographic densities: a case-control study. *AJR Am J Roentgenol.* 1987, 148, 1087-1092.
- [3] American College of Radiology. BI-RADS Breast Imaging Reporting and Data System. Virginia: Reston; 2003.
- [4] Electrical Impedance Tomography. IOP, 2005.
- [5] Cherepenin V, Karpov A, Korjnevsky A, Kornienko V, Mazaletskaya A, Mazurov D. A 3D electrical impedance tomography (EIT) system for breast cancer detection. *Physiological Measurement.* 2001, 22, 9-18.
- [6] Karpov A, Korjnevsky A, Mazurov D, Mazaletskaya A. 3D Electrical Impedance Scanning of Breast Cancer. *World Congress on Medical Physics and Biomedical Engineering, Chicago, 2000, 62.*
- [7] Dunaeva O, Gerasimov D, Karpov A, Machin M, Tchayev A, Tsofin Yu, Tsyplyonkov V. Using Backprojection Algorithm for 3D Image Reconstruction in EIT. *World Congress on Medical Physics and Biomedical Engineering, Munich, Germany, 2009.*
- [8] Korotkova M, Karpov A. Procedure for assessment of the mammary gland electrical impedance images. *XIII international conference on electrical bio-impedance. Graz, Austria, 2007.*
- [9] Gubler E. Quantitative methods for analysis and identification of pathology. Lenin-grad, 1978.

INTECH