

Diagnostic criteria for mass lesions differentiating in electrical impedance mammography

Karpov A, Korotkova M

Clinical Hospital #9

Yaroslavl, Russia

e-mail: kb9@mail.ru

Abstract. The purpose of this research was to determine the diagnostic criteria for differentiating volumetric lesions in the mammary gland in electrical impedance mammography. The research was carried out utilizing the electrical impedance computer mammograph «MEIK v.5.6»[®], which enables to acquire images of 3-D conductivity distribution layers within mamma's tissues up to 5 cm depth. The weighted reciprocal projection method was employed to reconstruct the 3-D electric conductivity distribution of the examined organ. The results of 3,710 electrical impedance examinations were analyzed. The analysis of a volumetric lesion included assessment of its shape, contour, internal electrical structure and changes of the surrounding tissues. Moreover, mammary gland status was evaluated with the help of comparative and age-related electrical conductivity curves. The diagnostic chart is provided. Each criterion is measured in points. Using the numerical score for evaluation of mass and non-volumetric lesions within the mammary gland in electrical impedance mammography allowed comparing this information to BI-RADS categories developed by American College of Radiology experts. The article is illustrated with electrical impedance mammograms and tables.

1. Introduction

Electrical impedance mammography is a relatively new method for breast diseases diagnostics (2, 4). In a short time period diagnostic criteria for early breast cancer detection were developed (3, 5), as well as the method for assessment and evaluation of electrical impedance images (6). Percentile curves of age-related electrical conductivity were built up for the mammary gland status evaluation (1). Currently, there emerged a necessity of a standardized description of volumetric lesions and developing of a system for volumetric lesions description in the mammary gland to be in line with ACR BI-RADS categories. The purpose of this research was to determine the diagnostic criteria for differentiating volumetric lesions in the mammary gland in electrical impedance mammography. Moreover, importance was attached to the assessment of the breast in case of non-volumetric lesions too.

2. Materials and Methods

The research was carried out utilizing the electrical impedance computer mammograph «MEIK v.5.6»[®], which enables to acquire images of 3-D conductivity distribution layers within mamma's tissues up to 5 cm depth. The weighted reciprocal projection method was employed to reconstruct the 3-D electric conductivity distribution of the examined organ (2, 4). At the same time, the mammary glands were examined with «Ultrasonix SP» ultrasound scanner. The results of 3,710 electrical impedance examinations were analyzed. Visual and quantitative assessment of images including the calculation of the mean electrical conductivity index (IC) / electrical potential was performed.

3. Result

Volumetric lesion is a dimensional lesion, detected in several scan planes. The analysis of volumetric lesion images included assessment of their shape, contour, internal electrical structure and changes of the surrounding tissues. Moreover, mammary gland status was evaluated using the comparative and age-related electrical conductivity curves.

A. Volumetric lesion.

1. *Volumetric lesion contours assessment in accordance with the terms of BI-RADS ACR: round, oval, lobular, irregular.*

For example, round – a lesion of a spherical, circular or spherical shape (Fig. 1). The size is determined by lesion's diameter. Typical example – a cyst.

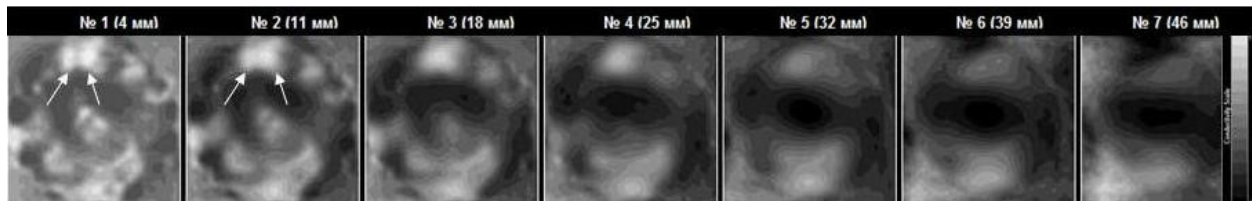


Fig. 1. EIM. Seven scan planes. In the upper segment at 12 on the clock dial, there can be observed two round hypoimpedance lesions (indicated with arrows).

2. *Assessment of volumetric lesion contours in accordance with the terms of BI-RADS ACR: sharp, vague, infiltrated.*

For example, infiltrated - the contours of a lesion are clearly distinguishable and are characterized by hyperimpedance (Fig. 2). Typical example – breast cancer.

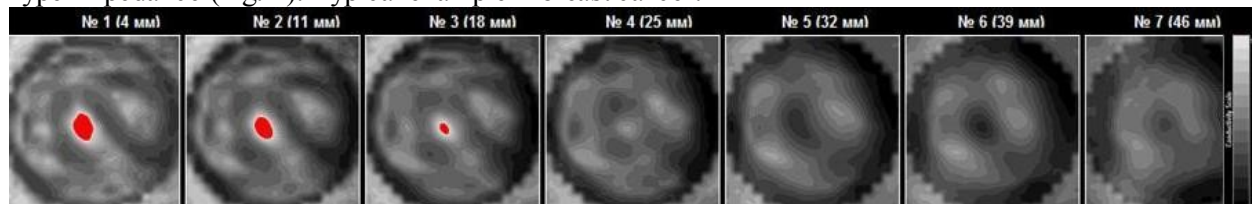


Fig. 2. EIM. Seven scan planes. The obovoid lesion is visualized at 3 on the clock dial (indicated

3. *Assessment of the internal electrical structure of a volumetric lesion in accordance with the terms of BI-RADS ACR: hyperimpedance, isoimpedance, hypoimpedance, animpedance.*

Taken separately, the internal electrical structure of the lesion is not the criterion for judging on its possible malignancy. However, it is an important characteristic, especially in combination with other evaluation criteria. The increase of electrical conductivity/potential is correlated with an increase of malignancy probability.

For example, animpedance - electrical conductivity/potential value of the lesion is considerably higher than that of the surrounding tissue of the breast (Fig. 3). Typical example – breast cancer.

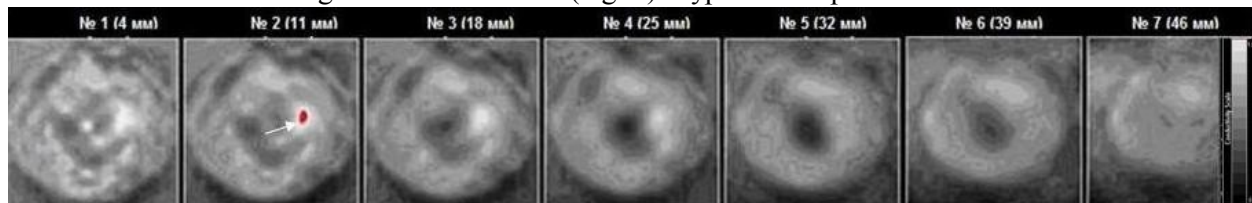


Fig. 3. EIM. Seven scan planes. In the outer segment of the left mammary gland, at 3 o'clock position there is observed an an-impedance area, which is highlighted with red in the second scan plane, less than 10 mm in size (indicated with arrows).

4. *Assessment of volumetric lesion influence on the surrounding tissue in accordance with the terms of BI-RADS ACR: skin thickening, skin extrusion or retraction, skin or nipple infiltration, alterations of the breast anatomy.*

For example, skin thickening – a pronounced unilateral hyperimpedance lesion either focal or located around the mammary gland (Fig. 4). Typical example – inflammatory breast carcinoma.

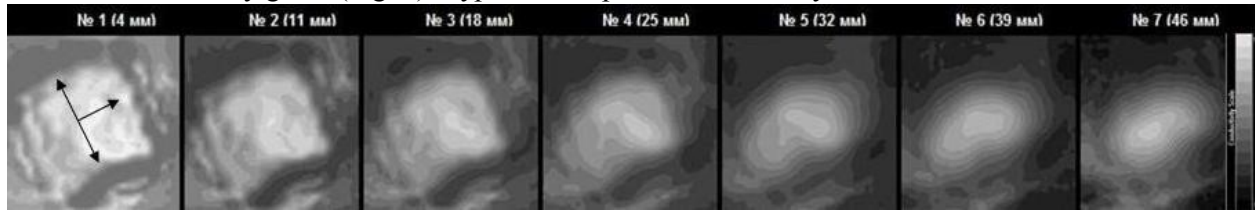


Fig. 4. EIM. Seven scan planes. A pronounced hyperimpedance contour around the mammary gland (indicated with arrows)

B. Comparative electrical conductivity.

Comparative conductivity is the alteration of electrical conductivity of one breast with respect to the other (Fig. 5). Typical examples – breast cancer, mastitis.

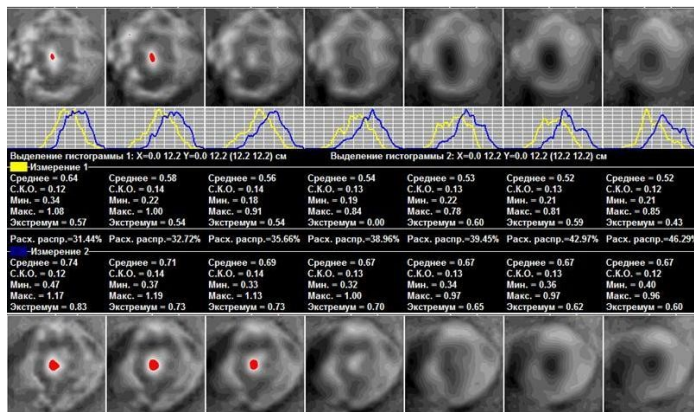


Fig. 5. Upper row – EIM. Seven scan planes. Breast cancer. Bottom row - EIM. Seven scan planes. Healthy gland. The second row shows the divergence between the histograms of electrical conductivity distribution of the affected and healthy mammary glands.

4. Conclusion

Diagnostic chart was created, in which each criterion was measured in points (Table 1).

Table 1. Diagnostic criteria for differentiating mass lesions in electrical impedance mammography (EIM).

Diagnostic criteria	Electrical impedance points
Shape	
• round, oval	1
• lobular, irregular	2
Contour	
• no	0
• sharp	1
• hyperimpedance, indistinct	2
Surrounding tissues	
• preserved	0
• structure alteration/displacement	1
• thickening/extrusion/retraction	2
Internal electrical structure	
• hyperimpedance ($IC < x - 2 \text{ std}$)	0

• isoimpedance ($IC = x \pm 2$ std)	1
• hypoimpedance ($IC > x + 2$ std)	2
• animpedance ($IC > x + 3$ std)	3
Comparative electrical conductivity	
• divergence between histograms < 20%	0
• divergence between histograms 20- 30%	1
• divergence between histograms 30-40%	2
• divergence between histograms > 40%	3

Using the numerical score for evaluation of volumetric and non-volumetric lesions within the mammary gland in electrical impedance mammography allowed comparing this information to BI-RADS ACR categories.

EIM	ACR
<i>Common scale</i>	<i>BI-RADS-categories</i>
no score	BI-RADS 0 poor image
0-1	BI-RADS 1 lesions are not defined – routine mammography
2-3	BI-RADS 2 benign tumours – routine mammography
4	BI-RADS 3 probably benign findings – in 6 months
5-7	BI-RADS 4 suspicious abnormality - biopsy
> 8	BI-RADS 5 highly suggestive of malignancy – treatment/biopsy

EIM numerical score allows for standardizing the description of volumetric lesions and for the usage of patient monitoring algorithm, developed by the American College of Radiology when conducting electrical impedance mammography. Thus, it may contribute to the compatibility of electrical impedance mammography with the well-established diagnostic methods and the uniformity of volumetric lesions differentiation by various methods.

References

- [1] Breast imaging reporting and data system (BIRADS) 2003 *American College of Radiology*
- [2] Cherepenin V, Karpov A, Korjnevsky A, Kornienko V, Mazaletskaya A, Mazurov D and Meister D 2001 A 3D electrical impedance tomography (EIT) system for breast cancer detection *Physiological Measurement* **22** 9
- [3] Dunaeva O, Gerasimov D, Karpov A, Machin M, Tchayev A, Tsofin Yu and Tsyplonkov V 2009 Using Backprojection Algorithm for 3D Image Reconstruction in EIT *World Congress on Medical Physics and Biomedical Engineering* **25** 288
- [4] Electrical Impedance Tomography 2005 Edited by Holder D 167
- [5] Karpov A, Korotkova M, Mumtazuddin Ahmed M, Myachin M and Tsofin Yu 2011 Seminar on electrical impedance potential mammography Yaroslavl
- [6] Korotkova M and Karpov A 2007 Procedure for assessment of the mammary gland electrical impedance images *XIII international conference on electrical bio-impedance* **17** 699